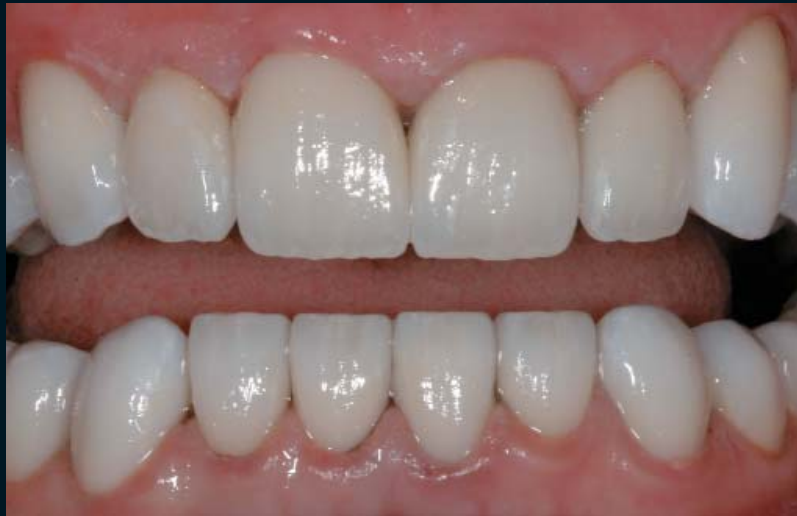

A DELAYED SUBOPAQUING TECHNIQUE FOR TREATMENT OF STAINED DENTITION: CLINICAL PROTOCOL

Edward Lowe, BSc, DMD*
Nelson Rego, CDT†
Juan Rego, CDT†



Teeth with severe tetracycline staining can present a restorative challenge to the clinician. While a variety of options facilitate predictable aesthetic treatment of patients with such dentition, they often require significant tooth reduction in order to provide the dentist and the laboratory technician with adequate space for the restorative material to conceal the discoloration. This presentation outlines an alternative to this treatment that uses resin cement to mask the discolorations prior to the cementation of the porcelain laminate veneers.

Learning Objectives:

This article discusses the use of resin cement to mask tetracycline discoloration prior to cementation of veneers. Upon reading this article, the reader should:

- Be able to understand and identify the alternative to treating tetracycline-stained dentition.
- Recognize the differences between immediate and delayed subopaquing.

Key Words: tetracycline, veneer, subopaquing, shade, aesthetics

* Private practice, Vancouver, British Columbia.

† Laboratory technician and owner, Smile Designs by Rego, Downey, California.

Edward Lowe, BSc, DMD, Vancouver Centre for Cosmetic Dentistry, 1011 Davie Street,
Vancouver, BC V6E 1M5, Canada
Tel: 604-683-2483 • E-mail: edlowe@axionet.com

Intrinsic staining of the dentition manifests itself following naturally occurring processes such as aging, disease, injury, and some exposures (eg, fluorosis, tetracycline).^{1,2} The latter, in particular, has been the impetus for some of dentistry's most challenging cases when patients request aesthetic enhancement of severely discolored dentition.³

Although tetracycline stains cannot be removed with polishing or abrasive mechanisms,³ dentition with tetracycline staining have responded favorably to whitening regimens.^{1,4,8} Despite the increased popularity of at-home vital bleaching tray systems,^{4,5} their use in enhancing the aesthetics of patients with tetracycline staining mandates that clinicians consider the shade and location of the discoloration,^{3,6} in addition to the appropriate length of treatment duration. This may require several weeks or months of disciplined use and may expose the patient to hard and soft tissue sensitivities.^{7,8}

Alternative modalities to correct the appearance of tetracycline-stained dentition include placement of all-ceramic veneers or crowns and direct composite materials. Contemporary treatments employing crowns and highly opaque porcelain veneers, however, have presented disadvantages in terms of their final aesthetics⁹ and less-than-conservative preparation designs to accommodate the porcelain thickness required to adequately mask the discoloration. In other instances, the use of composite resins with indirect restorations to opaque the underlying discoloration—although once considered a beneficial adjunct—have proven technique sensitive, inefficient, and invasive with regard to the need to remove additional tooth structure.¹⁰ Bleaching of the dentition prior to placement of the porcelain laminate veneers has also been accomplished.¹¹

The following presentation will demonstrate a new protocol for the restoration of severely tetracycline-stained dentition. This technique involves subopaquing the teeth at the *cementation* appointment rather than at the *preparation* appointment.

Immediate Versus Delayed Subopaquing

With the conventional subopaquing technique, one of the challenges encountered is placing acrylic provisional restorations. The acrylic provisionals tend to adhere to the composite resin, often making their removal challenging during the final seating appointment. Additionally, the composite is abraded at the seating appointment and silanated to couple the exposed glass particles in the composite prior to the placement of the

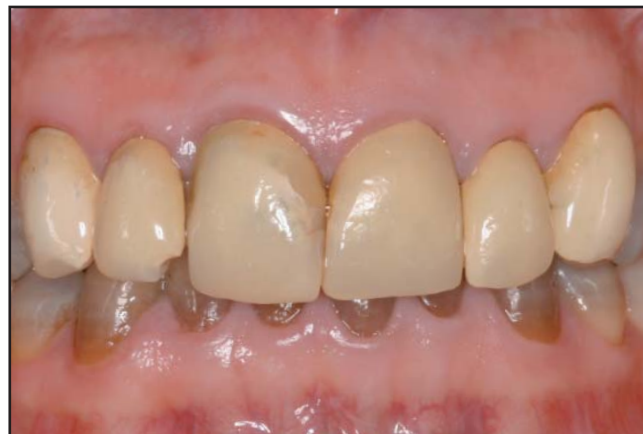

Figure 1. A 37-year-old female patient presented with concerns regarding her Class I occlusion and tetracycline-stained dentition.

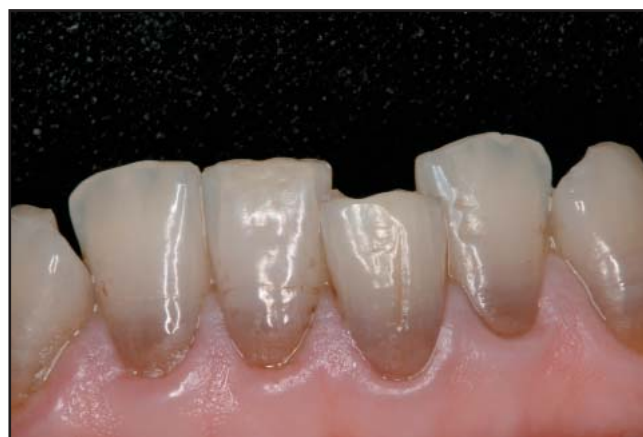

Figure 2. Moderate crowding was noted, but not crossbites. Canine guidance and contact in protrusive movements were present.

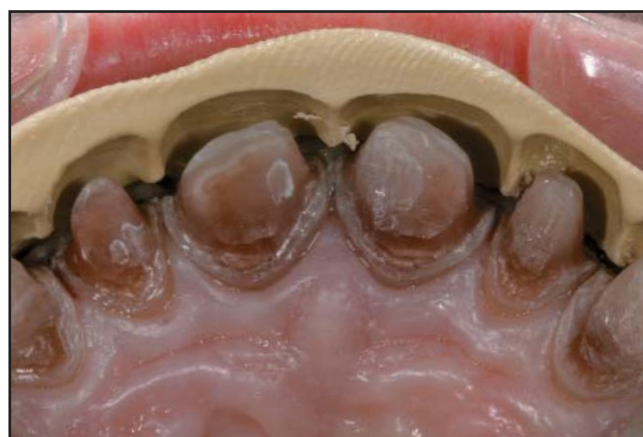

Figure 3. View of polyvinylsiloxane putty reduction matrix. Preparations were used to verify adequate incisal and proximal reduction.

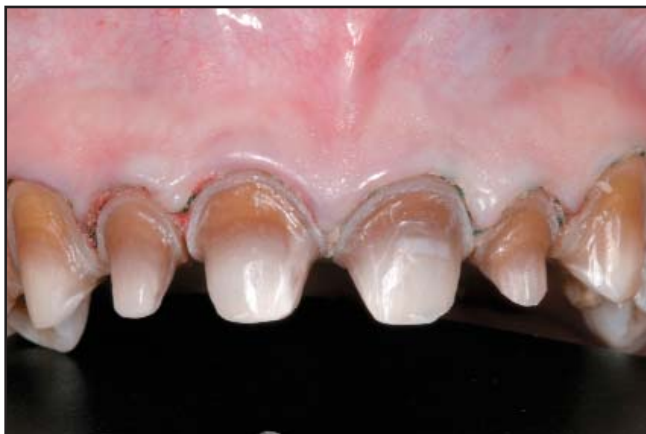

Figure 4. View of the completed maxillary anterior preparations with retraction cord in place.

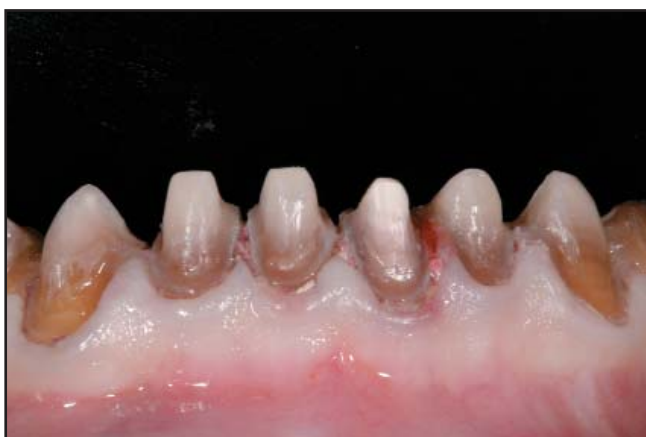

Figure 5. Facial view of the completed mandibular anterior preparations. The preparations should be cleansed and left slightly moist.

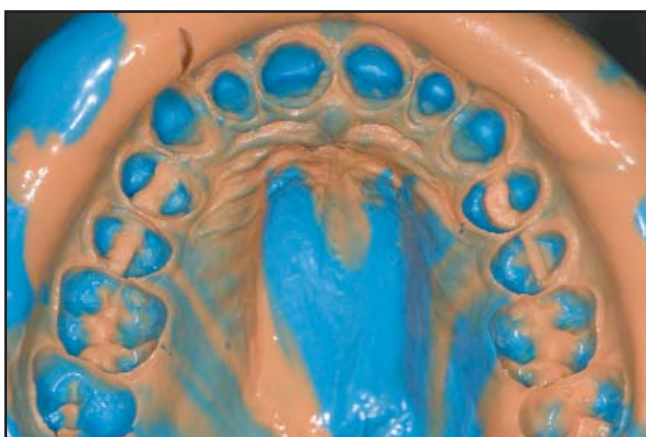


Figure 6. View of the final impression of the maxillary preparations. Note that all margins are clearly visible.

bonding agent and resin cement. This enhances the bond between the composite and resin cement. By subopaquing at the seating appointment, as proposed here, the resin cement is bonded to fresh composite—thereby maximizing the bond. In addition, the microetch and silanation steps are eliminated.

Further, with immediate subopaquing, if the shade of the masking composite is incorrect and the resin cement or the ceramic cannot alter the shade adequately, the subopaquing procedure may need to be repeated. This involves yet another assault on the dentin, which may affect the pulp and shorten the vitality of the tooth. By subopaquing at the seating appointment, the final shade of the restoration can be more precisely controlled with the try-in of various composite shades and the final restorations.

Considerations for Delayed Subopaquing

Uniform light yellow, brown, or gray tetracycline stains confined to the incisal three quarters of the crown can often be corrected with ceramics alone. Deep yellow, brown, or gray stain, without banding, may need some subopaquing or an opacious layer placed in the ceramic to mask the stain. Dark gray or blue stain with marked banding or more severe staining often requires both subopaquing and the selection of a ceramic that will mask the discoloration.¹²

Typically, however, staining that exhibits a dark blue cervical banding is the most challenging to correct in terms of color and location. As a result, the more difficult the stain is to block, the more opacious the selected ceramic material should be, keeping in mind that the compromise may be aesthetic.

Delayed subopaquing should be treatment planned from the beginning to allow for greater control over the final chroma and value of the restorative results. When the initial preparations are complete and the enamel is removed (if the shade of the dentin is darker than A4 and is going to shine through the ceramic), use of composite resin to obtain an A2 to A3 preparation shade at the final seating appointment is recommended. The decision to subopaque can also be made at the seating appointment if the desired results were not obtained.

Clinical Procedures

Diagnostic Evaluation and Treatment Planning

Initially, a comprehensive patient examination was conducted. Preexisting restorations that might otherwise conceal slight malpositioning of the dentition and require

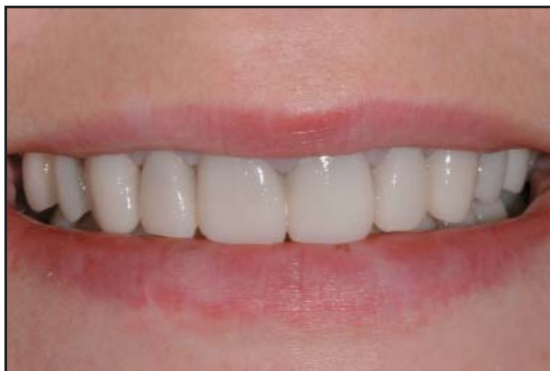

Figure 7. Facial view of the patient's smile with provisional restorations in place.

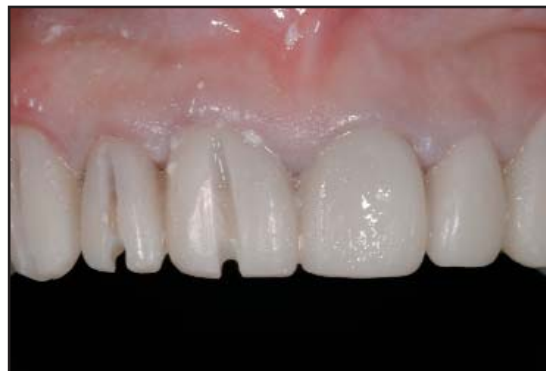

Figure 8. The provisional restorations were removed by imparting a slit down the center of the acrylic.

correction through the restorative process were identified (Figures 1 and 2). Gingival height and symmetry were also evaluated.

The anterior upper to lower cementoenamel distance was obtained to assess the existing occlusal vertical dimension.¹³ Then, based on these records and the patient's desires, the appropriate treatment modality was planned. In this case, 20 all-ceramic restorations (eg, IPS Empress, Ivoclar Vivadent, Amherst, NY; Authentic, MicroStar Corp., Lawrenceville, GA) were selected to restore teeth #4(15) through #13(25) and teeth #20(35) through #29(45). The teeth were mocked up to ideal length and incisal edge position using a flowable composite. Study models of the original teeth and the mocked-up teeth were obtained with a polyvinylsiloxane (PVS) impression material (eg, Status Blue, Zenith/DMG, Englewood, NJ; Aquasil Ultra, Dentsply Caulk, Milford, DE) and bite registration material in centric relation. A face-bow record was taken and sent to the laboratory with digital intraoral and extraoral photographs.

The laboratory poured the impressions and mounted them with the submitted records. A second set was poured and mounted to create a wax prototype of the case. The case was then returned with putty matrices of both arches and putty reduction guides of the wax prototype.

Shade Taking and Preparation Protocol

The shade of the existing teeth were observed in natural light and photographed (eg, Canon 20D, Canon Inc., Lake Success, NY; Nikon D70, Nikon Corp., Melville, NY) using the shade tabs as references, and using a colorimeter system (eg, ShadeVision, X-Rite, Grandville, MI; EasyShade, Vident, Brea, CA). Next, the putty matrices and reduction guides were tried in to verify fit.

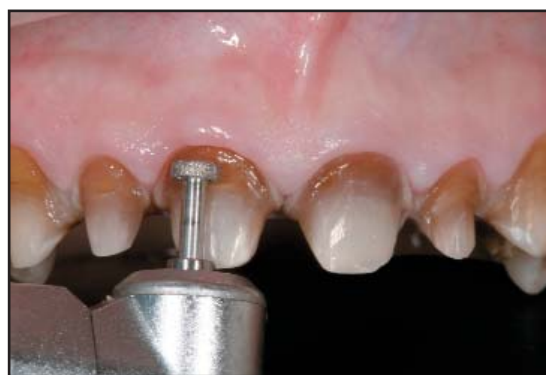

Figure 9. To accommodate the composite necessary to subopaque the veneers, a 0.5-mm depth cutter was used.

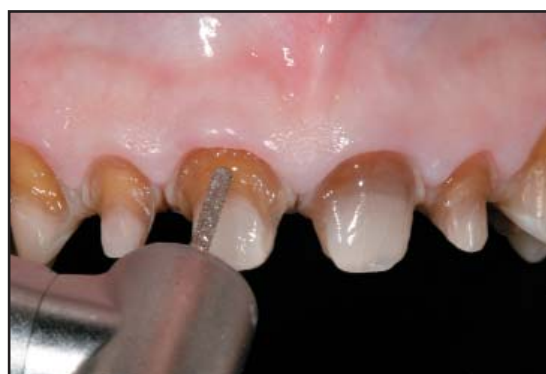

Figure 10. A coarse diamond bur was used to cut away the banding and create a 1-mm subgingival trough.

The patient was anesthetized and the maxillary and mandibular teeth were overlaid with a provisional acrylic using the putty matrices of the wax prototype. Depth cuts were placed in the facial surfaces of the maxillary anterior and premolar teeth with a 0.7-mm depth cutter. Incisal and proximal depth cuts of 1.5 mm and 1 mm,

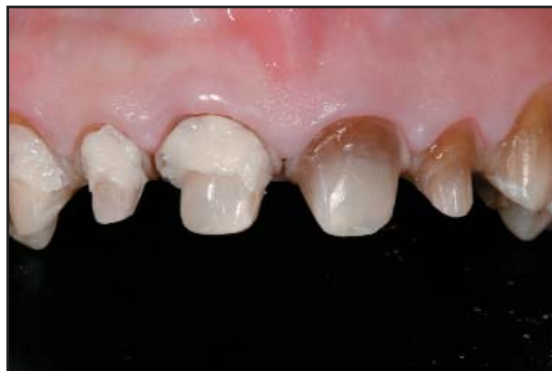

Figure 11. An opaque microhybrid composite was tried-in to the hollowed out area.

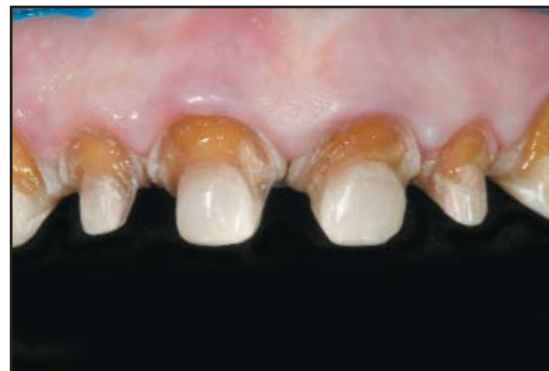

Figure 14. After final composite and cement shades were determined, the teeth were prepared for subopaquing.

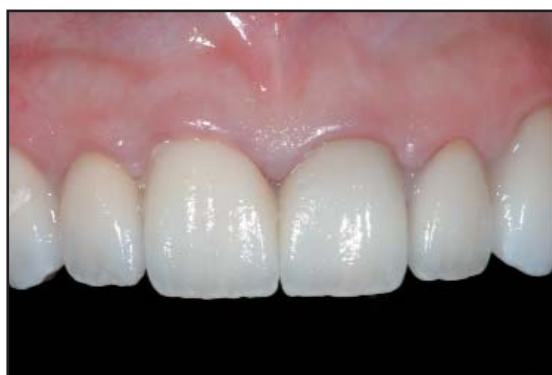

Figure 12. Half of the teeth were tried in with try-in paste, the others with paste only.

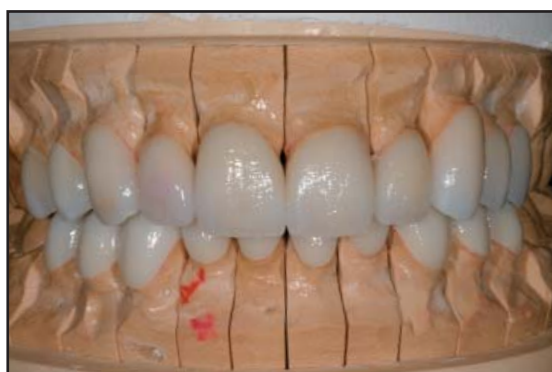

Figure 13. View of the definitive metal-free restorations on the working model.

respectively, were created with a supercoarse chamfer bur. This bur was also used to scribe the facial margins 1 mm supragingivally.

Once depth cuts were all joined together to prepare the incisal and facial surfaces, they were then made on the lingual surfaces of the teeth with the depth cutter,

and a coarse football shaped diamond bur was used to prepare the lingual surfaces of the maxillary anterior teeth. Next, the interproximal contacts were broken, and lingual surfaces were prepared in order to straighten malpositioned teeth through the preparation. The preparations were refined with fine finishing burs and polished with superfine diamond burs, carbide burs, and finishing disks (eg, Soflex XT, 3M Espe, St. Paul, MN; FlexiDiscs, Cosmedent, Chicago, IL).

Preparations were then verified for adequate incisal and proximal reduction using the putty reduction guide (Figures 3 through 5). The final impression was obtained using a PVS impression material (eg, Virtual, Ivoclar Vivadent, Amherst, NY; Aquasil Ultra, Dentsply Caulk, Milford, DE) in a stock tray (Figure 6).

Provisionalization

The provisional material was loaded into the putty matrix of the maxillary arch, placed over the preparations, and allowed to set for 2 minutes, after which the matrix was lifted off, along with the maxillary acrylic provisional restorations. Excess acrylic was removed, and the provisionals were placed back on the teeth until fully set. The provisionals were then removed and polished with disks, rubber cups and points (eg, Astropol, Ivoclar Vivadent, Amherst, NY; Diagloss, Axis Dental, Irving, TX) and brushes.

The mandibular dentition was then prepared in a similar manner. After the final impression was made of the mandibular preparations, bite registrations were obtained of the opposing preparations and the maxillary provisionals to the mandibular preparations. A stickbite was also taken (along with a photograph of the stickbite in place) to assist in establishing the incisal plane.

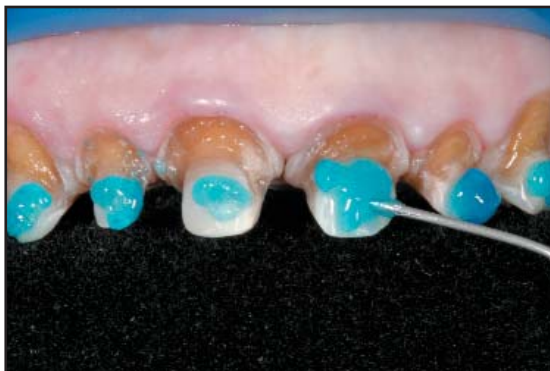

Figure 15. The tooth preparations were etched with 35% phosphoric acid.

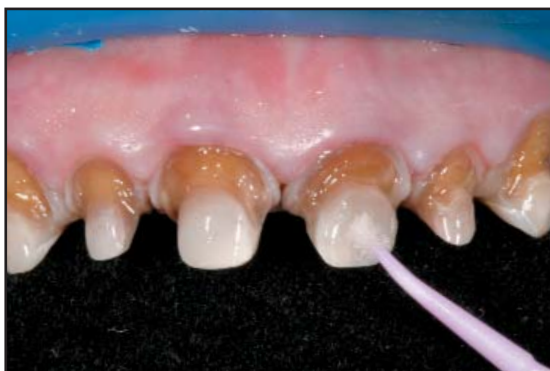

Figure 16. The single-component bonding agent was applied to the prepared dentition.

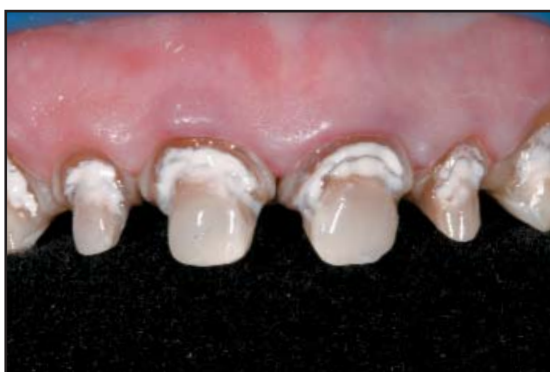

Figure 17. The opaquer composite and a red tint were mixed and applied to the depth of the trough.

Mandibular provisional restorations were also created similarly. The teeth were dried, and a desensitizing agent was painted on the teeth and lightly dried. The provisional acrylic remained on the teeth for 2 minutes, and then the matrix was gently removed. Once the margins were trimmed, the

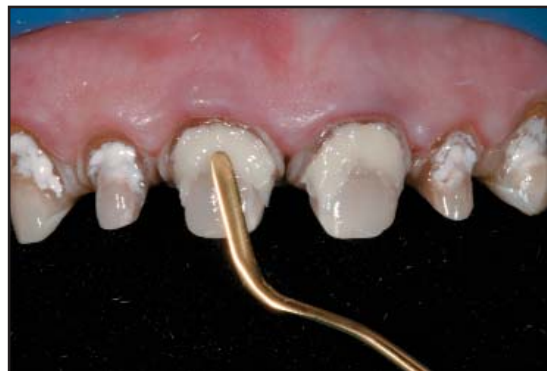

Figure 18. A microhybrid composite was added and filled almost to the level of the preparation.

provisionals were polished. A PVS bite was then taken of the maxillary preparations to the mandibular provisional restorations.

The maxillary provisional restorations were then cemented with provisional resin (eg, Provilink, Ivoclar Vivadent, Amherst, NY; Temp-Bond NE, Sybron Kerr, Orange, CA). The bite was adjusted to replicate conditions present when the acrylic overlay was initially placed, and impressions were taken of the final provisional restorations (Figure 7). Since the unprepared posterior dentition was in contact, and a face-bow record was obtained, the provisionals were given a final polish and a light-curable glaze (ie, BisCover, Bisco, Schaumburg, IL) was applied.

Laboratory Fabrication

The case was received at the laboratory, and all records were verified. Following model fabrication, the casts were mounted, and the bites were used to verify that the interocclusal records were consistent and accurate.

The case was then waxed using the approved temporaries. Since, in this case, the patient desired whiter and brighter teeth, the very dark nature of the underlying dentition required a level of opacity that blocked out the dark preparations. A pressed ingot (shade O2) provided the level of opacity required to block out the discolored dentition. An aggressive cutback of the pressed leucite-reinforced ingot was planned and implemented to facilitate extensive layering of different dentin and enamel shades, in order to create lifelike aesthetic restorations. The definitive restorations are etched with 10% hydrofluoric acid for 90 seconds, rinsed, dried, and inspected.

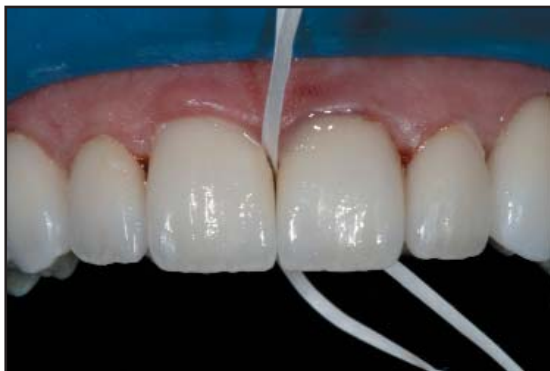

Figure 19. The restorations were flossed in order to remove interproximal residual cement.

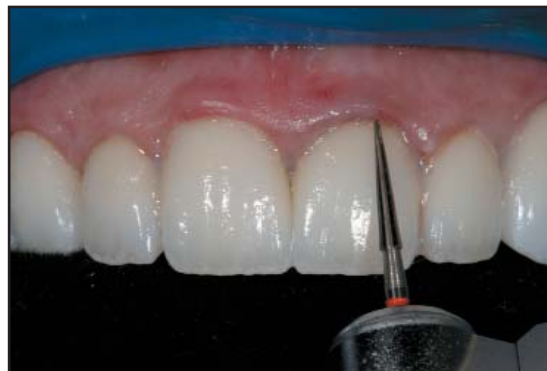

Figure 20. Once excess cement was removed, the margins were polished.

Cementation

When the restorations were returned from the laboratory, they were inspected for fit and color on the models. The provisional restorations were removed using hemostats (Figure 8), and the preparations were cleaned with 10% hydrogen peroxide.

At this time, the definitive restorations were tried in dry, one at a time. After trying in the restorations, it became evident that the color was not acceptable due to the deep chromatic banding at the cervical third that shined through, therefore subopaquing was planned for the seating appointment. The rationale for planning subopaquing at the seating appointment, rather than at the preparation appointment, is based on:

- Maintaining control over the underlying color and the final restoration;
- Use of fresh composite with more free radicals to promote adhesive bonding;
- Subopaqued composite not requiring microetching or silanization;
- Eliminating issues related to the possible adhesion of the provisional to the subopaquing composite.

A 0.5-mm depth cutter was used to cut into the cervical third of the affected preparations (Figure 9), and a coarse diamond bur was used to cut away the banding and create a 1-mm subgingival trough on the facial, extending to the lingual (Figure 10). Then, an opaque microhybrid composite was placed in the hollowed out area, almost to the level of the original preparation (Figure 11).

A white try-in paste was placed in the restoration, the veneers were placed on top of the preparations with the opaque hybrid composite, and shade was evaluated. A combination of hybrid composite and try-in paste were used to achieve the desired final shade (Figure 12).

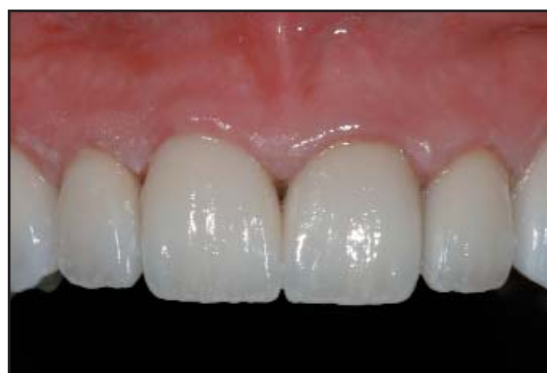

Figure 21. Facial view following completion of subopaquing and aesthetic enhancement.

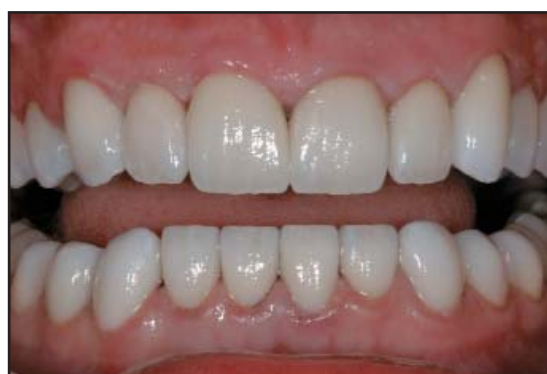

Figure 22. Two-week postoperative view of the patient's smile reveals the optimal shade match and aesthetics.

The final composite and cement shades were determined (Figure 13), and all teeth were prepared for subopaquing (Figure 14). The preparations were cleaned with a chlorhexidine scrub and rinsed. Rubber dam isolation was achieved, and the restorations were then conditioned with 35% phosphoric acid for 1 minute. After

rinsing and drying, the restorations were coated with silane for 1 minute and dried. A bonding agent was applied to the internal aspects of the restorations; excess solvent was then evaporated with a warm air dryer.

The preparations were etched with 35% phosphoric acid on the enamel and dentin for 15 seconds and 10 seconds, respectively (Figure 15), and then rinsed. The bonding agent was applied to the preparations (Figure 16), and then light cured for 10 seconds.

To begin the subopaquing process, the appropriate resin opaquer and tint were placed in the depth of the trough in a thin layer (Figure 17) to ensure the elimination of the dark dentin transmission to the overlying composite and ceramic. This opaque layer was cured for 10 seconds. Buildup of the subopaquing layer was continued using the selected composite, which was added to the preparation almost to the level of the preparation at try-in, but was not cured (Figure 18).

The selected cement was placed into the restorations seated on top of the composite-filled preparations. The restorations were spot tacked with a 2-mm tacking tip for 5 seconds per tooth, and applied with gentle apical pressure to ensure stable seating. The remaining restorations were seated, tacked, cleaned up in pairs, and then flossed through the contact twice and pulled through to the lingual to remove interproximal residual cement (Figure 19). This prevents possible dislodgement of the tacked restoration.

Glycerin was placed around the margins to ensure the oxygen inhibition layer was cured. The restorations were cured for 30 seconds on the buccal and 30 seconds on the lingual aspects with two halogen curing lights. After marking the facial surface of the restorations with a pencil, a #15 scalpel was used to remove the excess cement flushed out by the graphite. The margins were then polished with a #12 scalpel blade, an extrafine football shaped diamond bur, and an extrafine carbide finishing bur (Figure 20) to produce exceptional aesthetics (Figure 21).

The same cementation protocol was repeated for the mandibular restorations (Figure 22). Following seating of the mandibular restorations, occlusion should be verified and any necessary areas adjusted and polished with a porcelain polishing kit.

Conclusion

Subopaquing of veneer restorations that is performed at the seating appointment can provide clinicians with beneficial results in the treatment of patients with

severe tetracycline staining. In particular, this presentation has demonstrated the manner through which seating appointment subopaquing enables the clinician to maintain firm control over the underlying color and of the final restoration while utilizing fresh composites that promote the adhesive bonding process. The subopaquing composite does not require micro-etching or silanization and, when placed at the seating appointment, eliminates issues related to the possible adhesion of the provisional material to the subopaquing composite.

Although zirconium oxide materials that mask stained dentition do exist, they often require more tooth reduction and a full-crown preparation. Additionally, today's porcelain-fused-to-metal restorations, when properly fabricated, also provide aesthetic restorative alternatives in such cases. The subopaquing technique presented, however, enables clinicians to prepare for conservative veneers and partial-coverage restorations using a pressed ceramic for its optimal aesthetics and vital appearance.

References

1. Gerlach RW. Whitening paradigms 1 year later: Introduction of a novel professional tooth-bleaching system. *Compend Contin Educ Dent* 2002;23(1A):4-8.
2. Watts A, Addy M. Tooth discolouration and staining: A review of the literature. *Br Dent J* 2001;190(6):309-316.
3. Kugel G, Aboushala A, Zhou X, Gerlach RW. Daily use of whitening strips on tetracycline-stained teeth: Comparative results after 2 months. *Compend Contin Educ Dent* 2002;23(1A):29-34.
4. Marshall MV, Cancro LP, Fischman SL. Hydrogen peroxide: A review of its use in dentistry. *J Periodontol* 1995;66(9):786-796.
5. Haywood VB, Heymann HO: Nightguard vital bleaching. *Quint Int* 1989;20(3):173-176.
6. Haywood VB, Leonard RH, Nelson CF, Brunson WVD. Effectiveness, side effects and long-term status of nightguard vital bleaching. *J Am Dent Assoc* 1994;125(9):1219-1226.
7. Haywood VB, Leonard RH, Dickinson GL. Efficacy of six months of nightguard vital bleaching of tetracycline-stained teeth. *J Esthet Dent* 1997;9(1):13-19.
8. Haywood VB. Extended bleaching of tetracycline-stained teeth. *Contemp Esthet Rest Prac* 1997;1(1):14-21.
9. Okuda WH. Using a modified subopaquing technique to treat highly discolored dentition. *J Am Dent Assoc* 2000;131(7):945-950.
10. Nixon RL. Masking severely tetracycline-stained teeth with ceramic laminate veneers. *Pract Periodont Aesthet Dent* 1996;8(3):227-235.
11. Sadan A, Lemon RR. Combining treatment modalities for tetracycline-discolored teeth. *Int J Periodont Rest Dent* 1998;18(6):564-571.
12. Boksmán L, Jordan RE. Conservative treatment of the stained dentition: Vital bleaching. *Aust Dent J* 1983;28(2):67-72.
13. Rufenacht, CR. *Fundamentals of Esthetics*. Chicago, IL: Quintessence Publishing Co, 1992.

CONTINUING EDUCATION (CE) EXERCISE No. X



To submit your CE Exercise answers, please use the answer sheet found within the CE Editorial Section of this issue and complete as follows: 1) Identify the article; 2) Place an X in the appropriate box for each question of each exercise; 3) Clip answer sheet from the page and mail it to the CE Department at Montage Media Corporation. For further instructions, please refer to the CE Editorial Section.

The 10 multiple-choice questions for this Continuing Education (CE) exercise are based on the article "A Delayed Subopaquing Technique for Treatment of Stained Dentition: Clinical Protocol," by Edward Lowe, BSc, DMD, Nelson Rego, CDT, and Juan Rego, CDT. This article is on pages ###-###.

1. Patients presenting with tetracycline staining cannot be treated by:

- a. Whitening regimens.
- b. Polishing or abrasive mechanisms.
- c. All-ceramic crowns or veneers.
- d. Porcelain-fused-to-metal crowns or highly opaque porcelain veneers.

2. Challenges to conventional or immediate subopaquing may include:

- a. Acrylic provisionals adhering to the dentin.
- b. Use of the correct binding agent.
- c. Having to abrade and silanate the masking composite prior to cementation.
- d. All of the above

3. The dental laboratory pours two sets of models using the provided PVS impressions to:

- a. Have a backup model in case the originals were lost.
- b. Create a wax prototype of the case.
- c. Keep in case the clinician accuses lab of altering casts.
- d. Keep for permanent records in case of lawsuit.

4. The laboratory provides putty reduction guides to:

- a. Provide the dentist with a reliable way to verify incisal and proximal reduction.
- b. Allow dentist a way to verify fit of final restorations.
- c. Determine the final aesthetics of case.
- d. All of the above.

5. A very high level of opacity is required when:

- a. Patients desire natural-looking restorations.
- b. Trying to match the shade of a single central incisor.
- c. A patient has not done chairside bleaching.
- d. Trying to block out dark or discolored preparations.

6. Shade taking is accomplished using:

- a. The naked eye and shade tabs in natural light.
- b. A colorimeter system.
- c. Digital photography.
- d. All of the above.

7. Malpositioned teeth are straightened by:

- a. Depth cuts of greater than 0.7 mm.
- b. 2 mm or greater incisal reduction.
- c. Breaking interproximal contacts and then preparing lingual surfaces.
- d. Not preparing the lingual surface.

8. Which of these statements is NOT true? Occlusal adjustment is carried on the provisionals until the:

- a. Provisionalized teeth are not occluding.
- b. Provisionals are in contact evenly.
- c. Unprepared posterior teeth are in contact.
- d. Patient is comfortable.

9. The depth of the subgingival trough on the facial of the affected preparations is:

- a. 0.5 mm.
- b. 1.0 mm.
- c. 1.5 mm.
- d. 2.0 mm.

10. Which of the following statements is false? At final cementation, the masking composite is:

- a. Built almost to the level of the cervical third preparation in the tooth.
- b. Cured prior to the cementation of the restoration with resin cement.
- c. Cured along with the cementation of the restoration with resin cement.
- d. Placed over the cured opaquer layer.